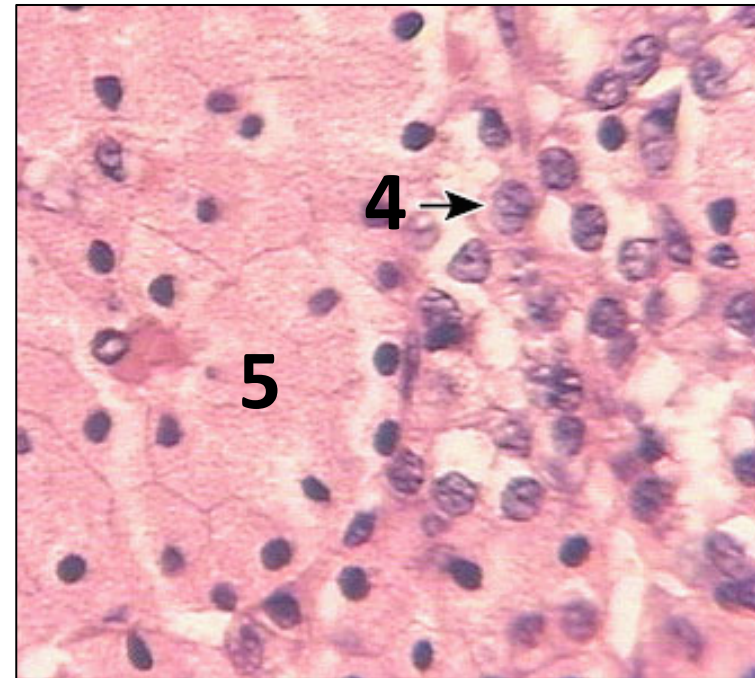
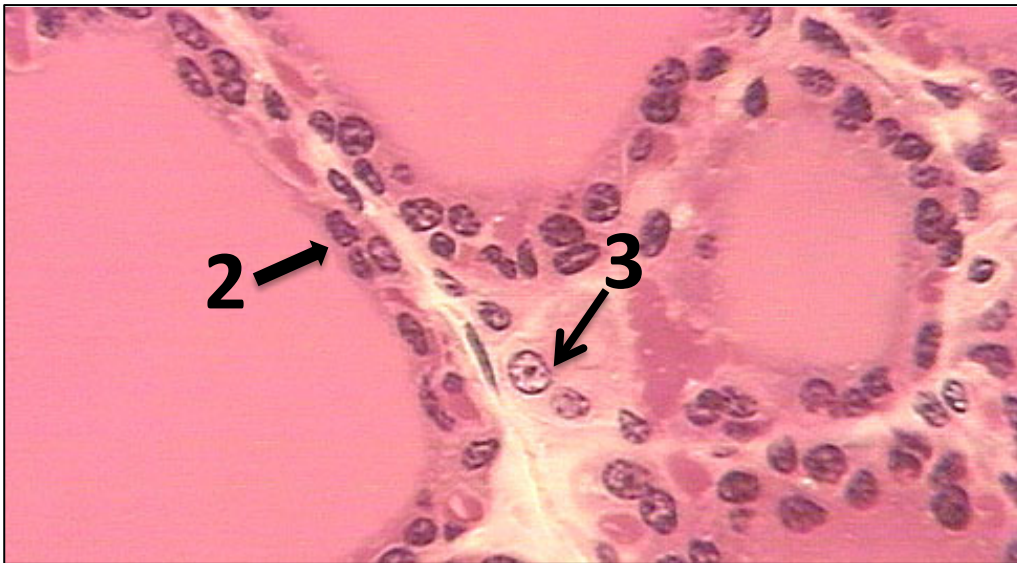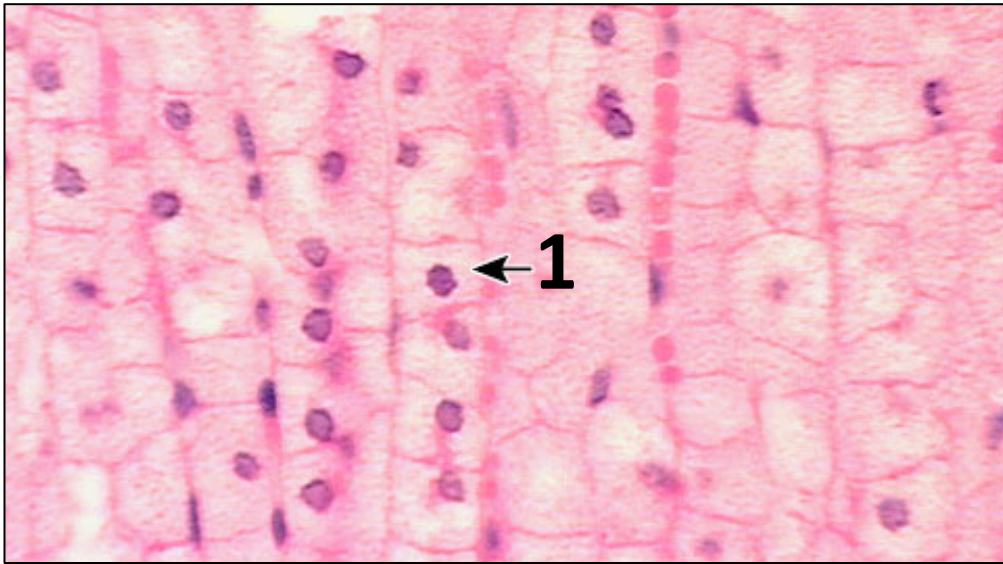


# Objectives

- Students are to work in teams of their choosing or individually.
- These exercises provide cases that allow students to **apply** their knowledge of **endocrine concepts to clinical scenarios** that may involve *more than one* endocrine system.
- It will provide **practice identifying the cell types** in endocrine organs.
- Students will explore specifically:
  - The structure, function, and regulation of the **adrenal, pineal, thyroid, and pituitary** gland.
  - The effects of medication, head injury, and blindness on endocrine cells.
  - How different endocrine cells produce and store their hormones.
  - How endocrine dysfunction can be clinically tested.

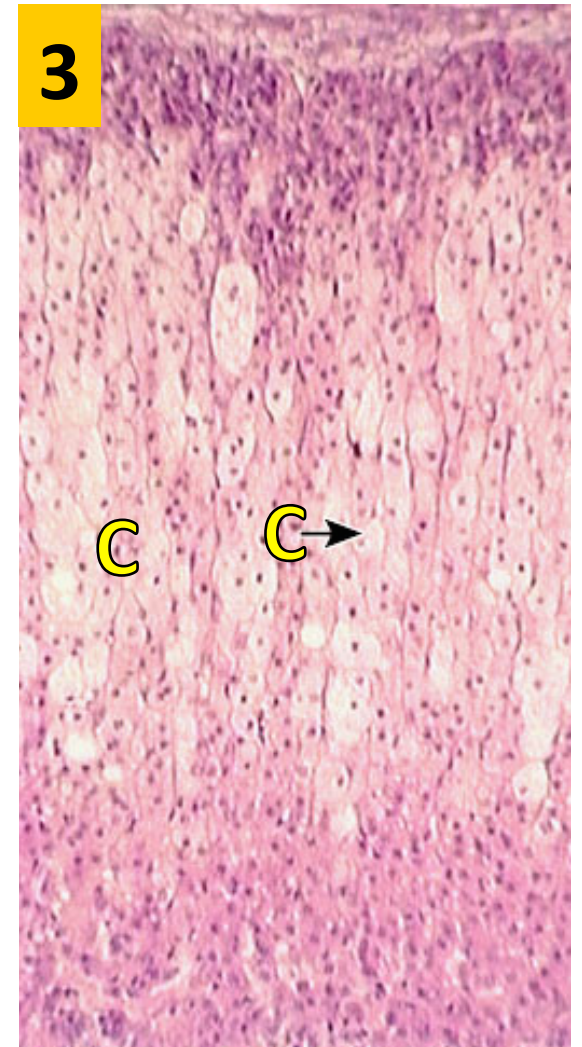
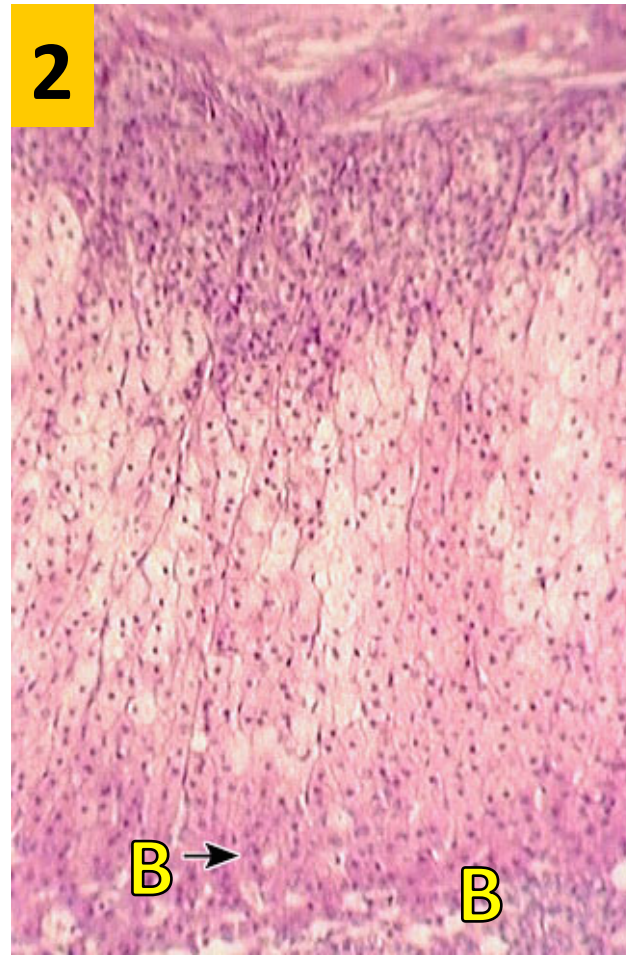
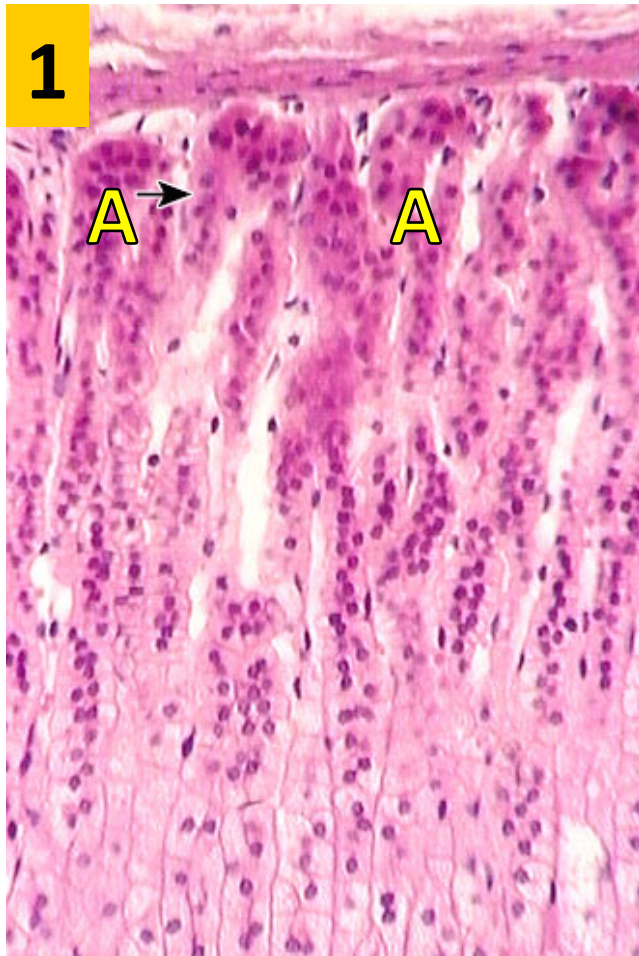


### **PROPERTIES:**

- A. Produces hormone with mitochondria and smooth endoplasmic reticulum
- B. Stores hormone outside the cell
- C. Stores hormone in granules
- D. Produces hormone with ribosomes on endoplasmic reticulum (rough ER)

Work in teams for **5 minutes**. Identify the numbered cells. For each numbered cell-type, chose its property(ies) from those listed. Each cell might have more than one property.





Work in teams for **5 minutes** and identify the **organ** and its **regions** in the photomicrographs above.

Your female patient complains of facial hair. You suspect a tumor of cells in which region (yellow letter) \_\_\_\_\_ and/or overproduction of:

- A. Adrenocorticotropin
- B. Cortisol

- C. Aldosterone
- D. Angiotensin II

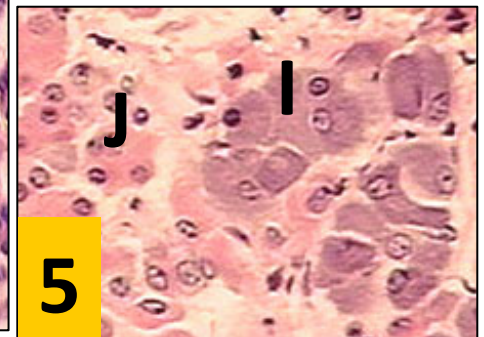
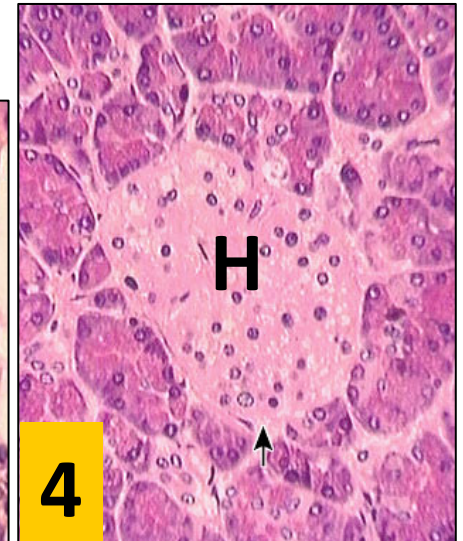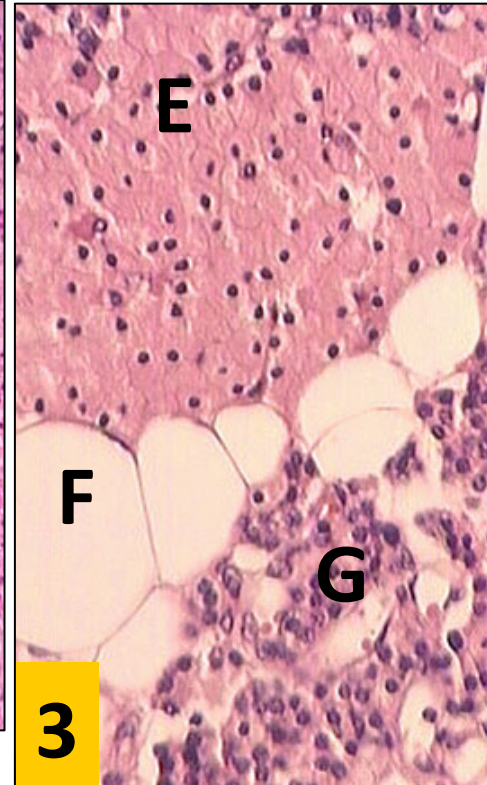
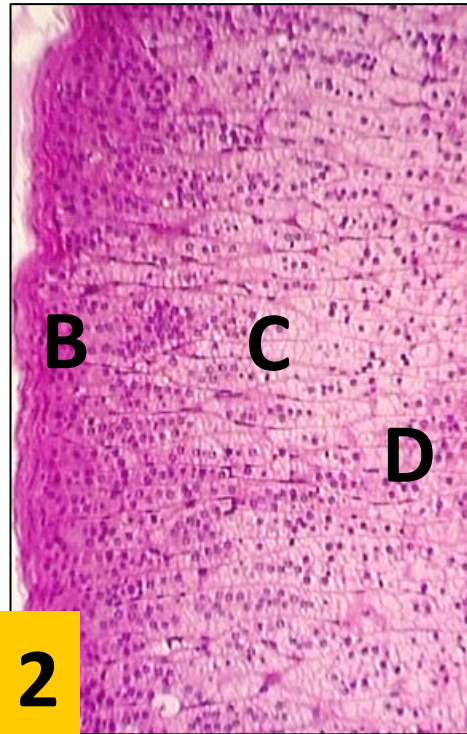
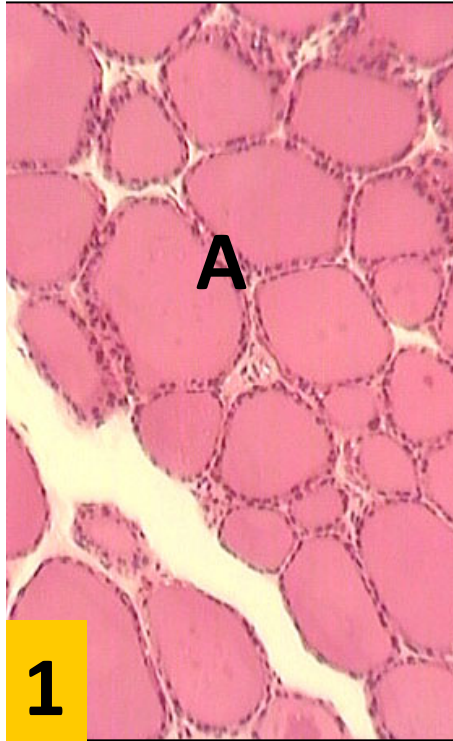
- E. Dehydroepiandrosterone

# Case 1. Expressive Dysphasia

- Mrs. Jane Martin was taken to the ER after finding herself unable to speak during a job interview.
- Her written history informed the medical team that she was anxious about the interview and was taking amiodarone for a heart condition.
- Mrs. Martin had an irregular tachycardia confirmed as atrial fibrillation on electrocardiogram. She was diagnosed with a left cerebral hemisphere stroke (causing the expressive dysphasia) secondary to atrial fibrillation. The atrial fibrillation was treated.
- Clinical examination revealed a diffusely enlarged thyroid gland. Blood tests showed that the concentrations of circulating thyroid hormones were high (total  $T_4$  310 nmol/l, NR 55–150 nmol/l) and the peripheral concentration of TSH was low (<0.05 mU/l, NR 0.5–4.0 mU/l). There were no detectable anti-thyroid autoantibodies.



## Case 1—Expressive Dysphagia, Cont'd



Take **10 min** with your small group to discuss this case and to identify each of the endocrine organs above.

Which organs/regions/cells shown here might have been most involved in Mrs. Martin's condition during her interview?

Write down the name of each **hormone** below. Then place beside it the correct letter of the **organ, region, or cell-type** shown above that produces it. Which hormone(s) is(are) most likely involved in Mrs. Martin's condition?

Parathyroid hormone  
Calcitonin

Glucagon  
Cortisol

Thyroxine  
ACTH

Amiodarone taken by Mrs. Martin contains 30% by weight of iodine, (essentially 500X the normal intake), which stimulated her thyroid gland.

Work in teams for **2 minutes** to study this electron micrograph, and answer the following question:

Which **yellow letter** labels the site in this electron micrograph where in iodine is added to thyroglobulin?

**KEY:**

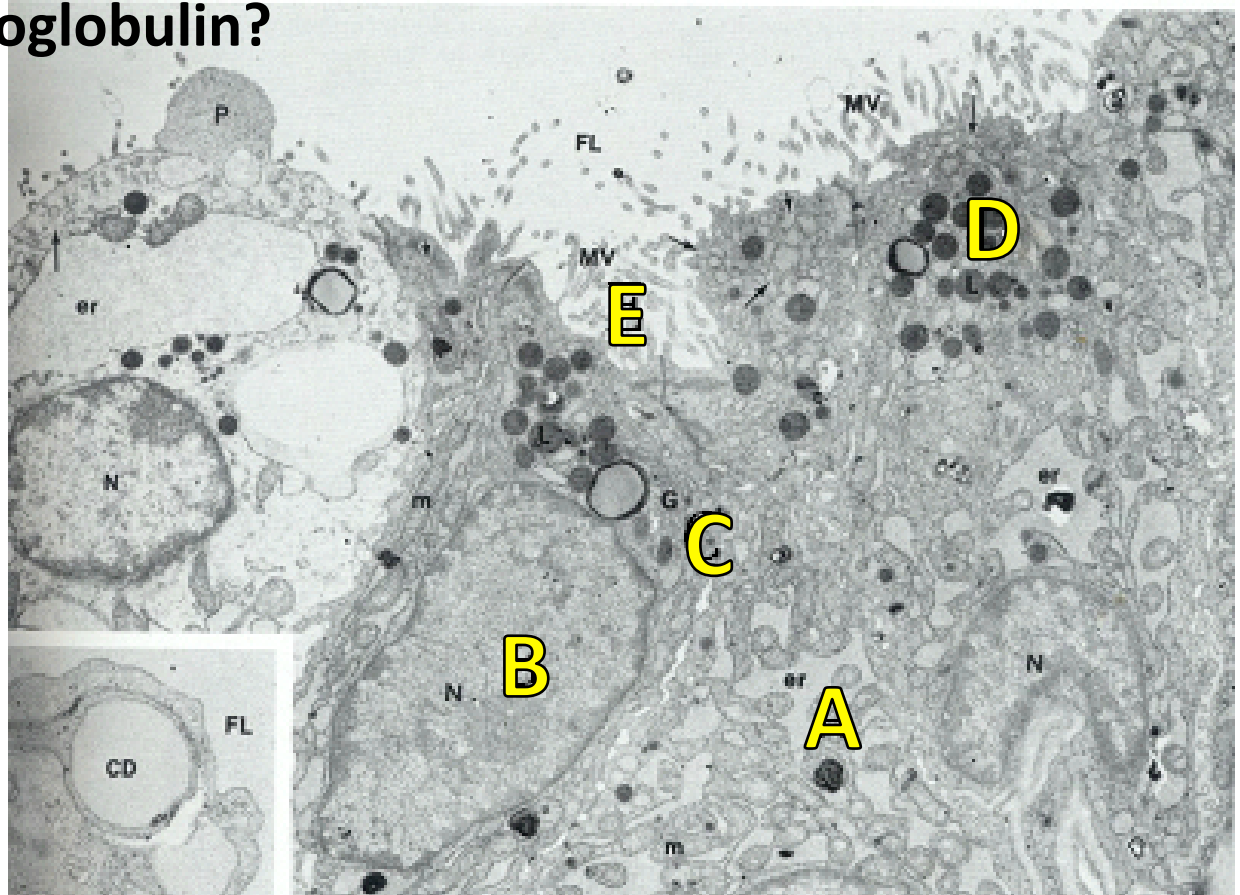
**A** = ER

**B** = nucleus

**C** = golgi

**D** = granules

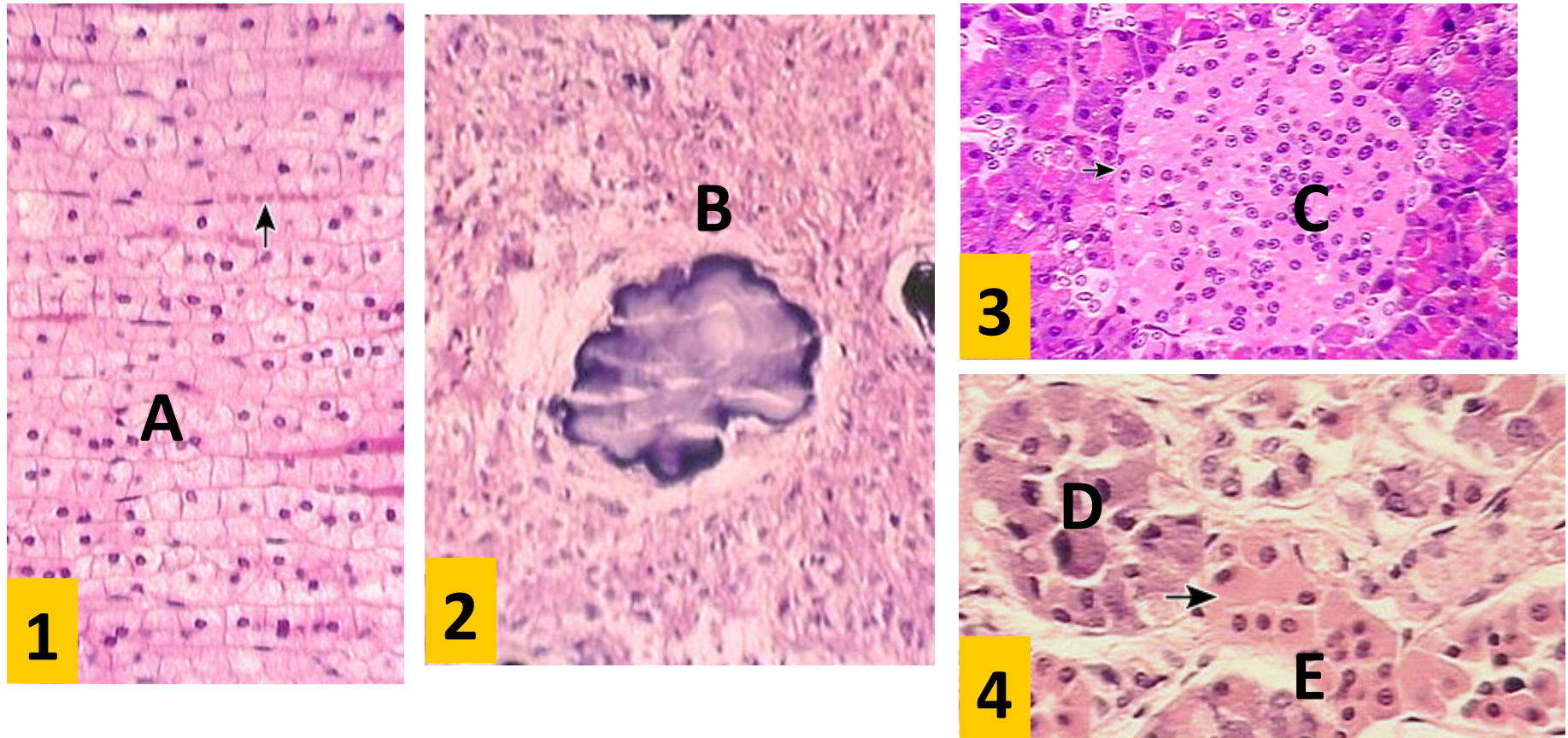
**E** = microvilli





# Case 2: Non-24

A 7-year-old boy was seen in the long-term follow up clinic. At age 5, an optic nerve glioma had been removed resulting in blindness, with no perception of light. The parents were concerned because his sleep pattern was disrupted, and he was disturbing the entire family by getting up in the night to play.



Work in teams for **3 minutes** and identify each organ/region indicated by the letters. A hormone produced by which of these could help improve this boy's day and night rhythms. What is the name of the hormone?

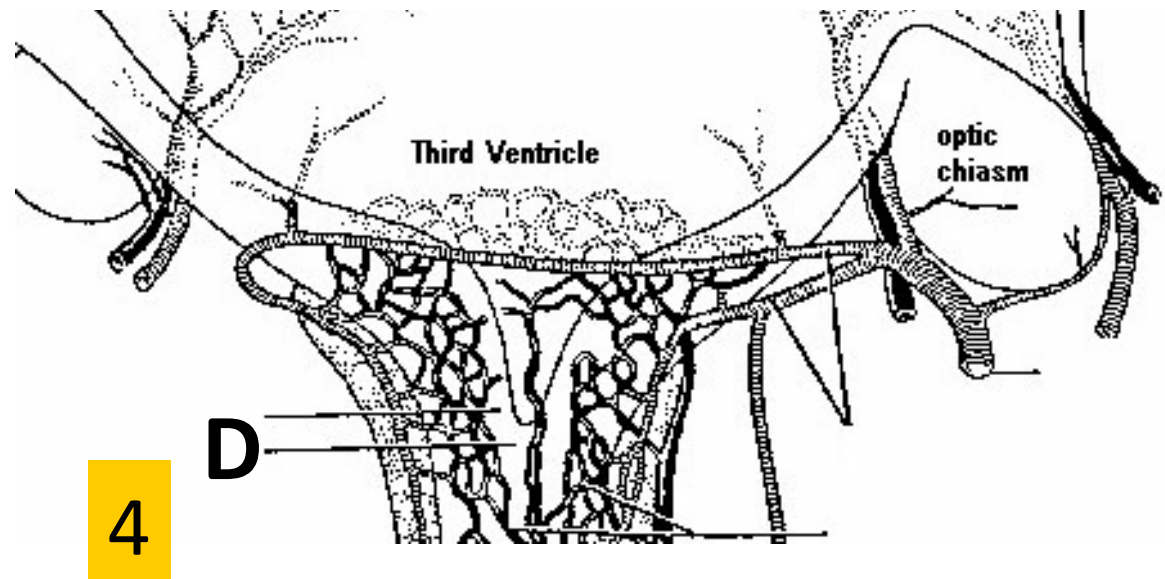
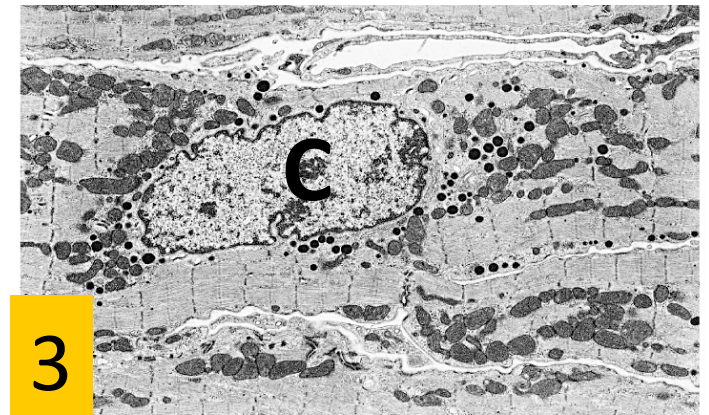
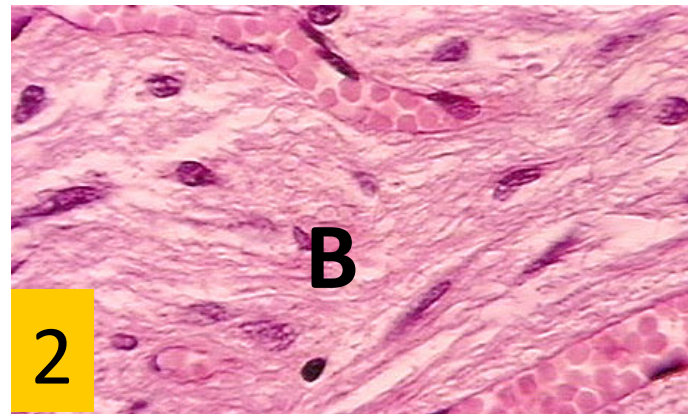
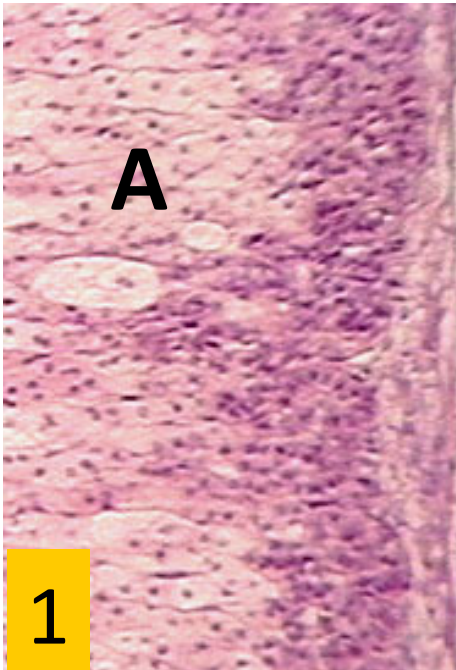
## Case 3. Good Reason to Wear a Helmet.



George Moore, a 26-year-old man, was admitted to the hospital via the Emergency Department with extreme fatigue and malaise. Some 7 weeks earlier he had been seen in the same department following a road traffic accident in which he had been knocked off his bicycle by a car. He was normally employed in the computer industry, and his fiancée reported a general decrease in his intellectual abilities. When examined, there were no focal neurological signs, and an emergency CT scan of his head was normal. He was normotensive with no abnormal physical signs; his blood pressure was 120/80 mmHg both lying and standing. His serum sodium was reported to be 109 mmol/l (NR 135–145 mmol/l). Work in teams for **15 minutes** on the remaining slides.

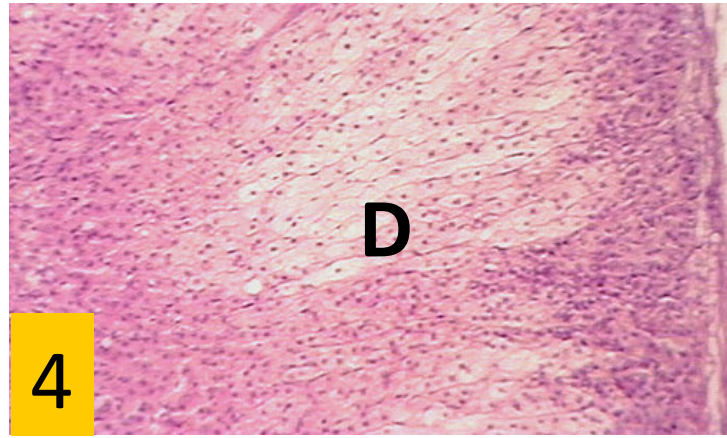
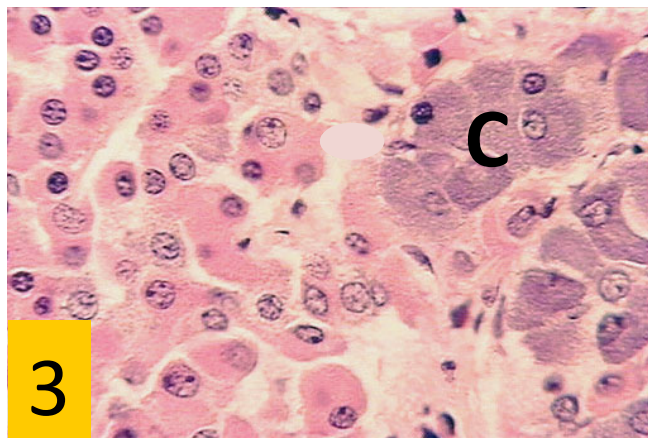
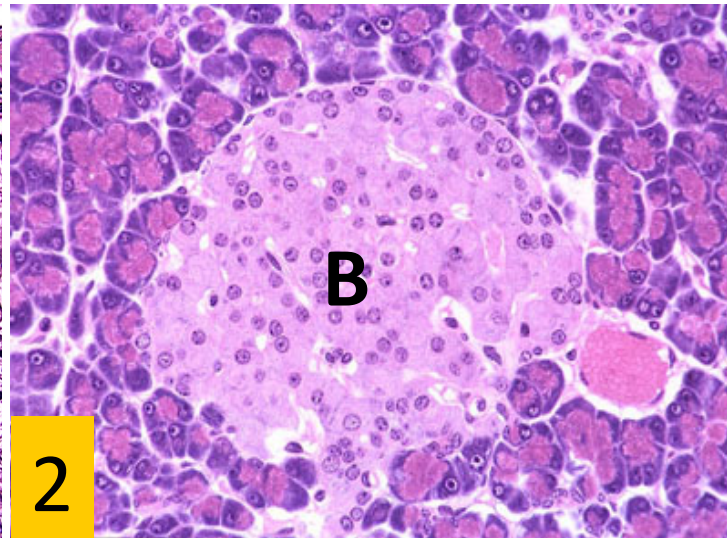
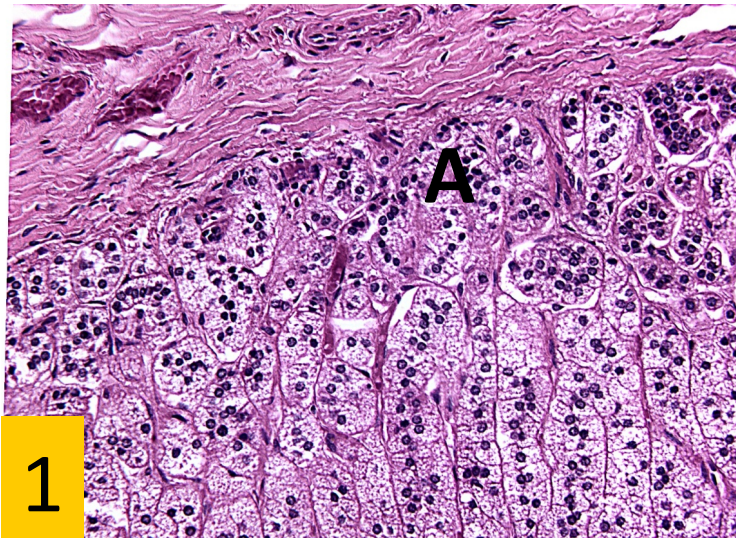


Because there was no evidence for a large oral intake of fluids or loss of any body fluids, one of the working diagnoses was that Mr. Moore's condition was caused by the accident and the head injury that resulted in loss of hormonal secretions into or from the:



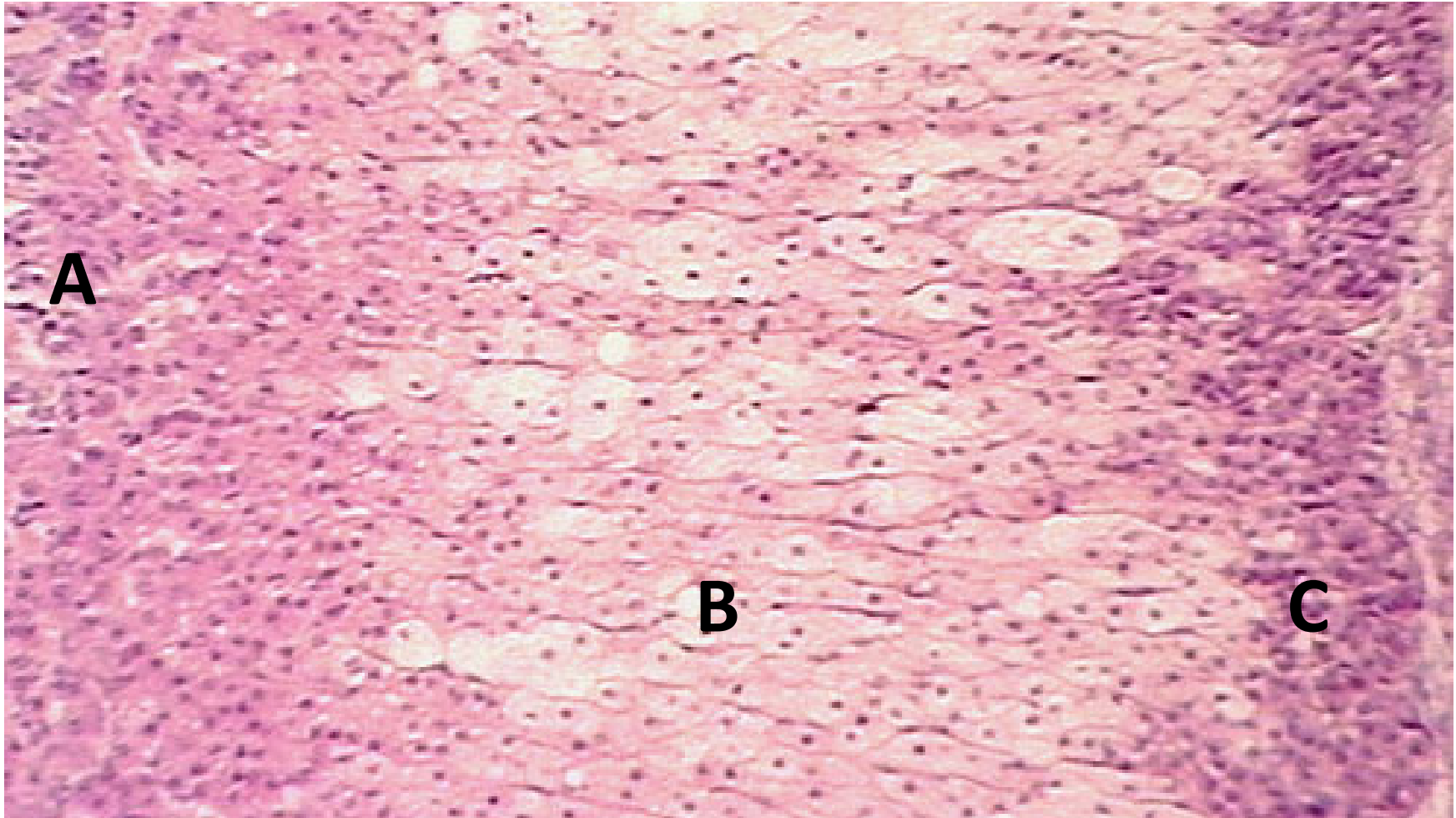


However, the endocrinologists also suspected Addison's disease. They tested for this with tetracosactrin, an analog of ACTH. After stimulation with tetracosactrin, serum cortisol rose from unmeasurable levels to 123 nmol/l after 5 days (NR >1000 nmol/l). This test confirmed Addison's disease, which involves hormones secreted by cells of which two lettered regions below?



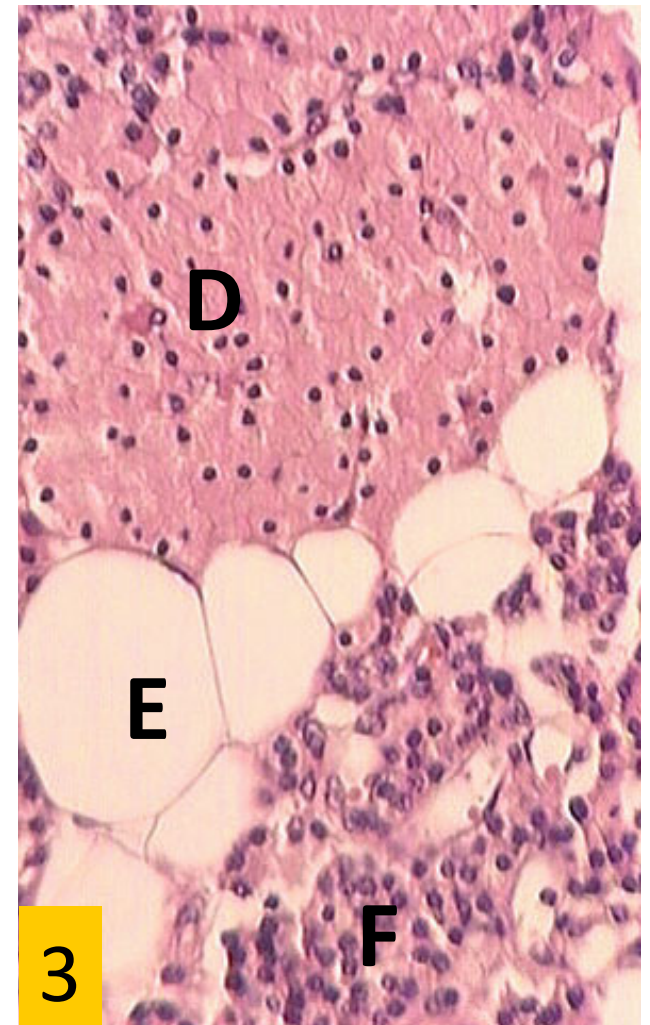
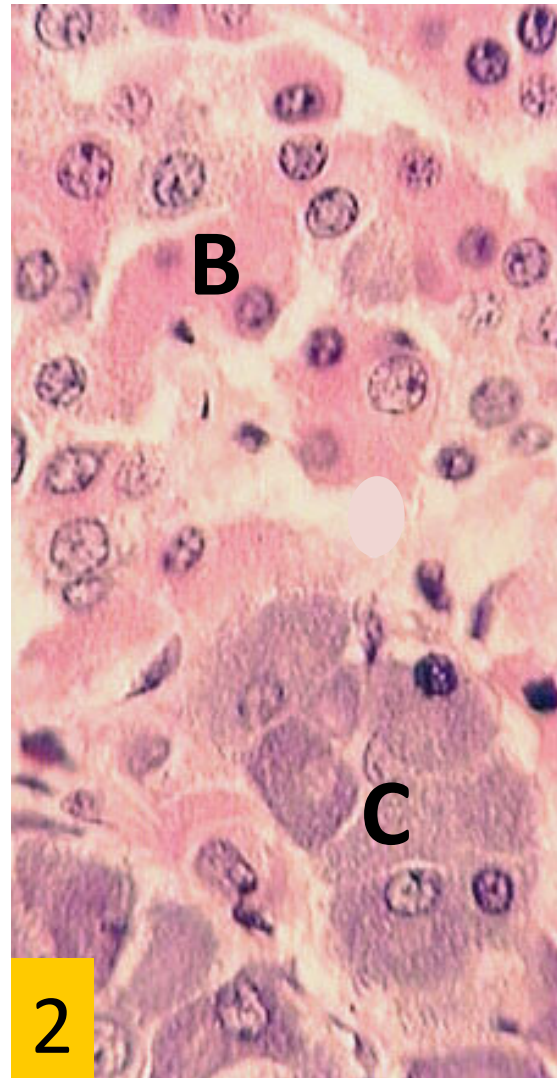
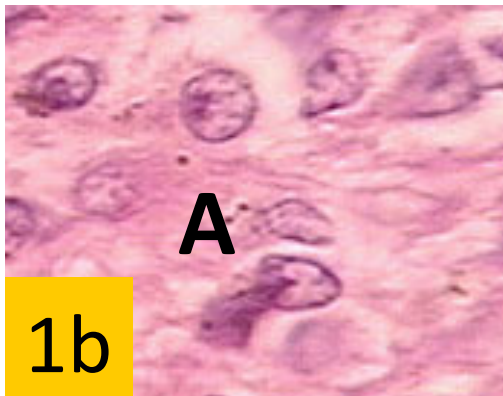
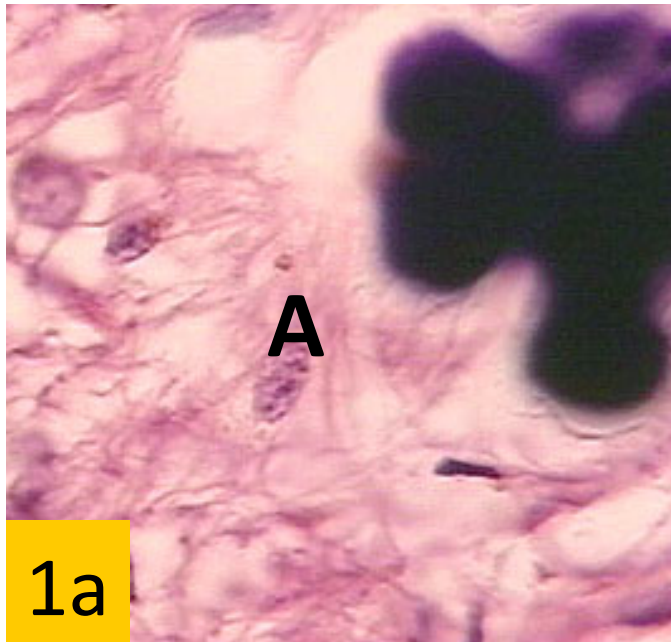
- A. A and B
- B. B and C
- C. A and D
- D. B and C
- E. C and D





Identify the lettered regions above, and name the hormones produced by each region and their basic function(s).

Based on Mr. Moore's symptoms and responses to tetracosactrin, it can be surmised that cells in the which of these regions are under functioning?



Because of the head injury, pituitary function tests were also performed. Mr. Moore was both hypogonadal and growth hormone deficient. An MR scan of the pituitary gland showed that it was normal, indicating that the problem was in the hypothalamus. Based on his deficiencies, which of the above cell types were affected?